

QUALITY IMPROVEMENT REPORT

SLIDING SIGN INITIATIVE

FACILITATING EARLIER DETECTION OF
ENDOMETRIOSIS USING DYNAMIC ULTRASOUND

DR. EMILY PANG, MD, FRCPC

DR. ALISON HARRIS, MBCHB, FRCPC

DR. CAROLINE LEE, MD, FRCPC



THE UNIVERSITY
OF BRITISH COLUMBIA

Vancouver
CoastalHealth

BACKGROUND

- Endometriosis affects an estimated 10% of reproductive age female patients, and can have a significant negative quality of life impact. Unfortunately, delays in diagnosis of 5-10 years is common because of non-specific symptoms
- Nearly all patients undergo a pelvic ultrasound at some point during the workup of their symptoms. Unfortunately, routine pelvic ultrasound is limited for assessment of endometriosis as it generally relies on static images
- Specialized ultrasound – incorporates dynamic maneuvers and pain mapping for endometriosis specific assessment, but only available at specialized centers
- A dynamic component of the specialized ultrasound called the sliding sign – evaluating for mobility between the posterior uterus and rectum, has a reported sensitivity and specificity for posterior cul-de-sac obliteration (a typical feature of deep endometriosis) of 85% and 98% respectively.

PROJECT AIM

To incorporate the sliding sign maneuver into the routine pelvic ultrasound assessment of patients who have risk factors for endometriosis presenting to our tertiary care hospital ultrasound department, and have this consistently performed and reported correctly in 80% of eligible patients by Oct 2023.

Goal is to screen for posterior cul-de-sac obliteration, which has a high association with deep pelvic endometriosis, and facilitate earlier diagnosis and management.

Outcome measures

- % of eligible cases where the sliding sign is performed correctly
- % of eligible cases where the sliding sign is reported/interpreted correctly
- % of abnormal sliding sign patients newly diagnosed with endometriosis

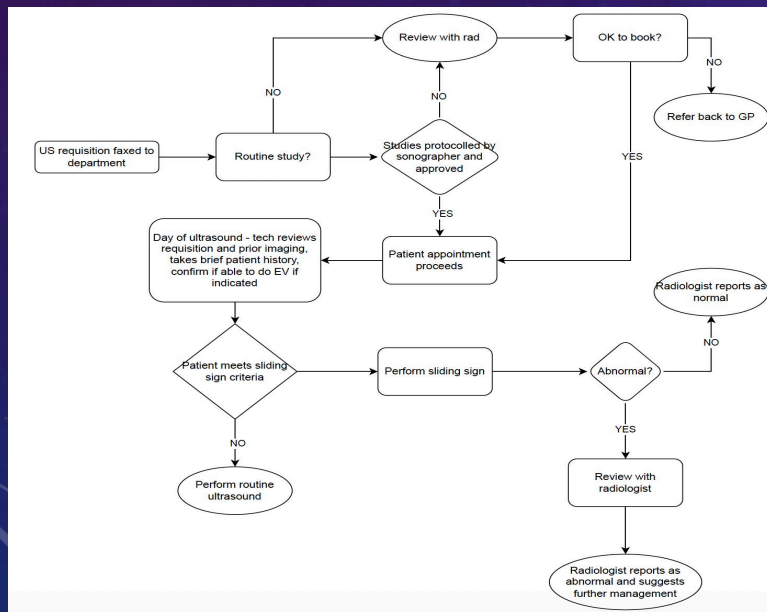
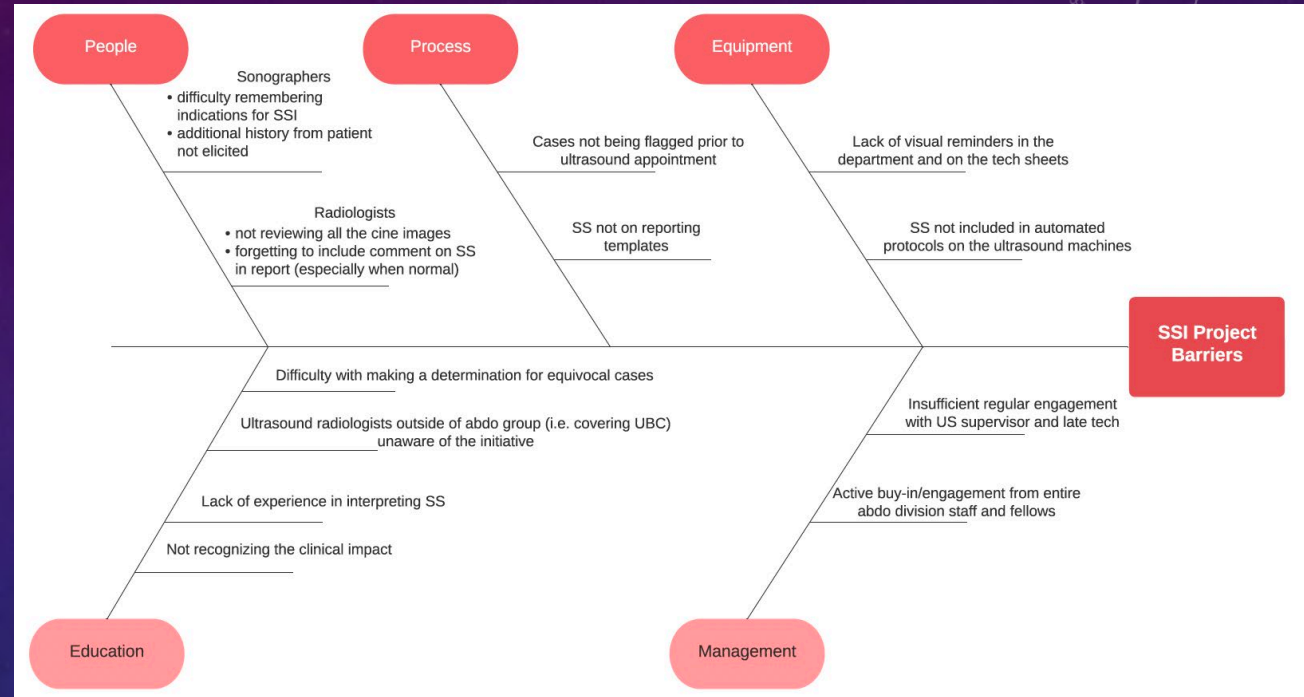
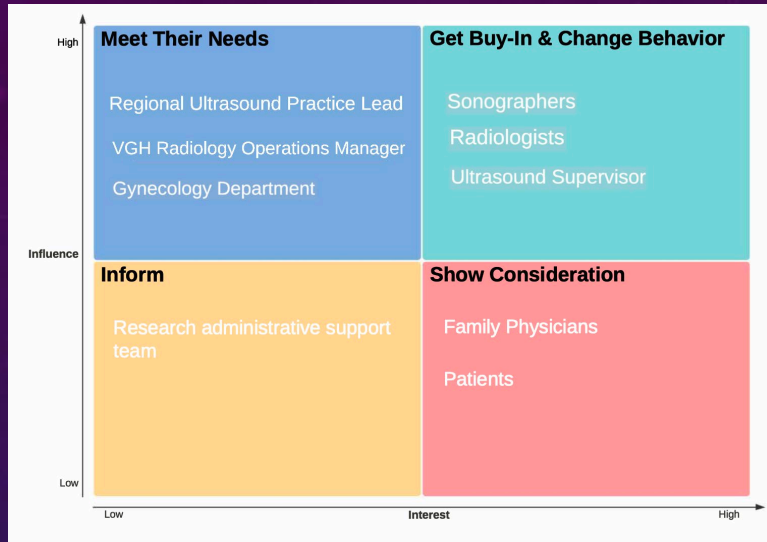
Process measures

- % of eligible cases where the sliding sign was performed
- % of eligible cases where the sliding sign was mentioned in the report

Balancing measures

- Additional time added to each ultrasound
- False abnormal (false positive) cases

DEVELOPING CHANGE IDEAS



Left top – Stakeholder matrix, sorting potential stakeholders by level of influence and interest

Left bottom – Process diagram describing the process from receiving an ultrasound requisition to performing and reporting an ultrasound including the sliding sign

Right top - Fishbone diagram illustrating potential barriers to change including:

- Difficulty remembering the indications for SSI prior to starting US
- Lack of physical reminders – tech sheet, reporting template
- Limited buy-in from stakeholders, only one champion in the department, awareness gap

METHODS

PDSA CYCLE 1

Project initiation Oct 2021

- Information gathering and consultation with stakeholders
 - Sonographers, gynecology, radiology
- Development and distribution of new protocol
 - Eligible patients - Adult, premenopausal, able to undergo endovaginal ultrasound with one or more of the following: 1) Non-acute pelvic pain, 2) Infertility, 3) Known history of TOA/PID (estimated 3x risk of endometriosis), 4) Specific request (i.e. suspected endometriosis)
- Educational sessions (jointly presented by radiology and gynecology)
 - Discuss rationale, eligible patients, how to perform the sliding sign
 - Inservice presentation for sonographers, rounds presentation to radiologists/trainees

Imaging Protocol:

Perform routine transabdominal and Endo-vaginal Ultrasound to pelvis
In addition, provide two (2), approximately 5 second cine clips to demonstrate posterior (rectovaginal/rectouterine) sliding sign in the sagittal plane.



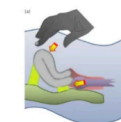
1. Cine clip focused to retro-cervical region (if uterus anteverted) - <https://www.contemporaryobgyn.net/view/retroverted-uterus-positive-sliding-sign> (see link for example)
2. Cine clip focused to anterior rectum sliding against posterior fundal uterus (if uterus retroverted). <https://www.contemporaryobgyn.net/view/anteverted-uterus-positive-sliding-sign> (see link for example)

Please refer to attached diagrams for additional reference.

Technical Tips to consider:

- Utilize footswitch on ultrasound units to allow anchoring free hand on the patient's abdomen while performing the endo-vaginal ultrasound.
- Adjust imaging filters to remove smoothing. This will create a "grainy" image but will allow the observation of sliding interfaces more easily.
- Communicate any site tenderness during mobility assessment to reporting Radiologist.

the 'sliding sign' in an anteverted uterus (a)



Gentle pressure is placed against the cervix using the transvaginal probe, to establish whether the anterior rectum glides freely across the posterior aspect of the cervix (retrocervical region) and posterior vaginal wall. If the anterior rectal wall does so, the 'sliding sign' is considered positive for this location.

A portion of the memo distributed to ultrasound department members describing the new protocol

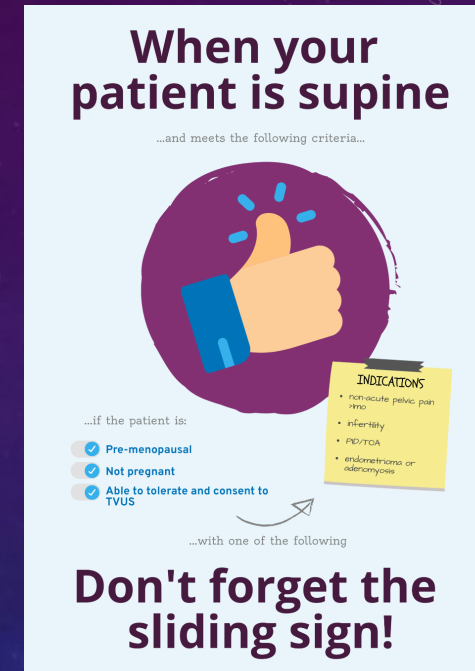
METHODS

PDSA CYCLE 2 Feb 2023

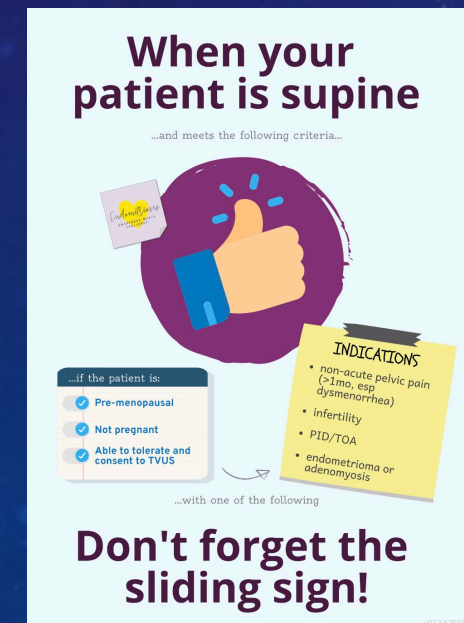- Feedback - Difficult to remember to perform SS and specifically the eligibility criteria, by the time the radiologist reviews the case it is too late as EV done
- Intervention
 - Reminder posters put up in the endovaginal probe sanitation room
 - **Rationale:** Any sonographer needing to perform an EV ultrasound would see the poster
 - **Implementation:** consulted sonographers re: optimal poster placement, posters printed and placed

PDSA CYCLE 3 Mar 2023

- Feedback – eligibility criteria vague, time gap between seeing the poster and performing US
- Intervention
 - New placement in individual ultrasound rooms at probe cover storage - more immediate reminder
 - Posters revised for visibility in lower light conditions
 - Updated and clarified eligibility criteria



Version 1 (top) and 2 (bottom) of reminder posters



METHODS

PDSA CYCLE 4 July/August 2023

- Feedback - non abdominal-specialty radiologists not consistently reporting sliding sign result even when performed by sonographer – awareness gap
- Intervention
 - Personal communication, approach individually to “pitch” the initiative and encourage reporting even if normal

PDSA CYCLE 5 October 2023

- Feedback – request for a reference guide
- Intervention
 - Create a user guide and reference for radiologists less familiar with sliding sign, distribute via e-mail
 - Create shared macro in dictation software for when an abnormal sliding sign is encountered

VGH/UBCH Ultrasound

Sliding Sign Initiative

A USER'S GUIDE



WHAT IS IT? The sliding sign is a dynamic ultrasound maneuver used to assess mobility between the uterus and rectum.



WHY WE DO IT? Absence of the sliding sign indicates adhesions in the posterior cul-de-sac, which can have a number of causes but most notably deep endometriosis.

 Evaluating the sliding sign in patients who have risk factors for endometriosis may help to detect the disease earlier.

WHO? Adult female patients who are premenopausal, not pregnant, able to undergo endovaginal ultrasound, and present with one or more of the following:

- ✓ Chronic pelvic pain > 1 month (especially dysmenorrhea)
- ✓ Infertility
- ✓ History of pelvic inflammatory disease/tubo-ovarian abscess
- ✓ Known or newly discovered adenomyosis or endometrioma
- ✓ Known history of endometriosis

Sample pages from sliding sign reference document

Reporting an Abnormal Sliding Sign

There is an abnormal posterior uterine sliding sign, which raises the possibility of advanced endometriosis or other cases of posterior cul-de-sac adhesions. If clinical symptoms are consistent with endometriosis, gynecological follow-up is suggested for further assessment and to evaluate the need for further imaging such as MRI.

EXAMPLE IMPRESSION

**If normal, can just mention in the body of the report unless there is a specific query about endometriosis/sliding sign in the requisition*

METHODS

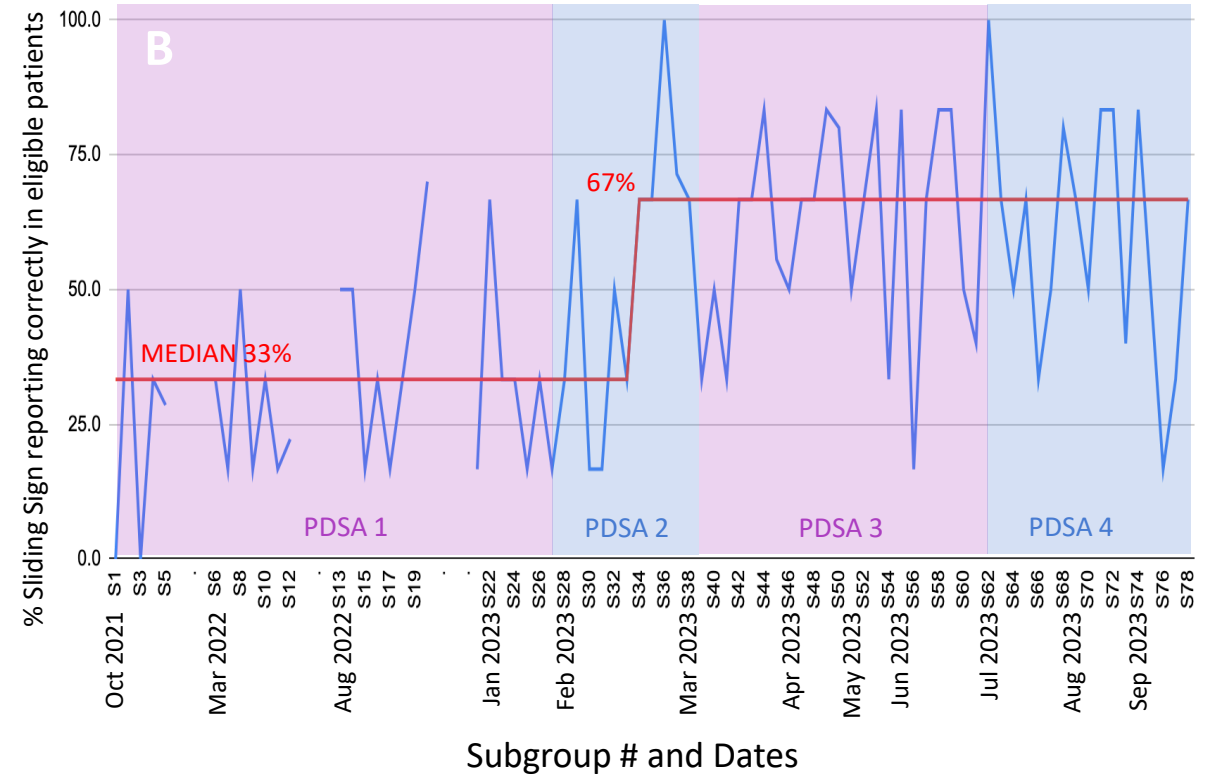
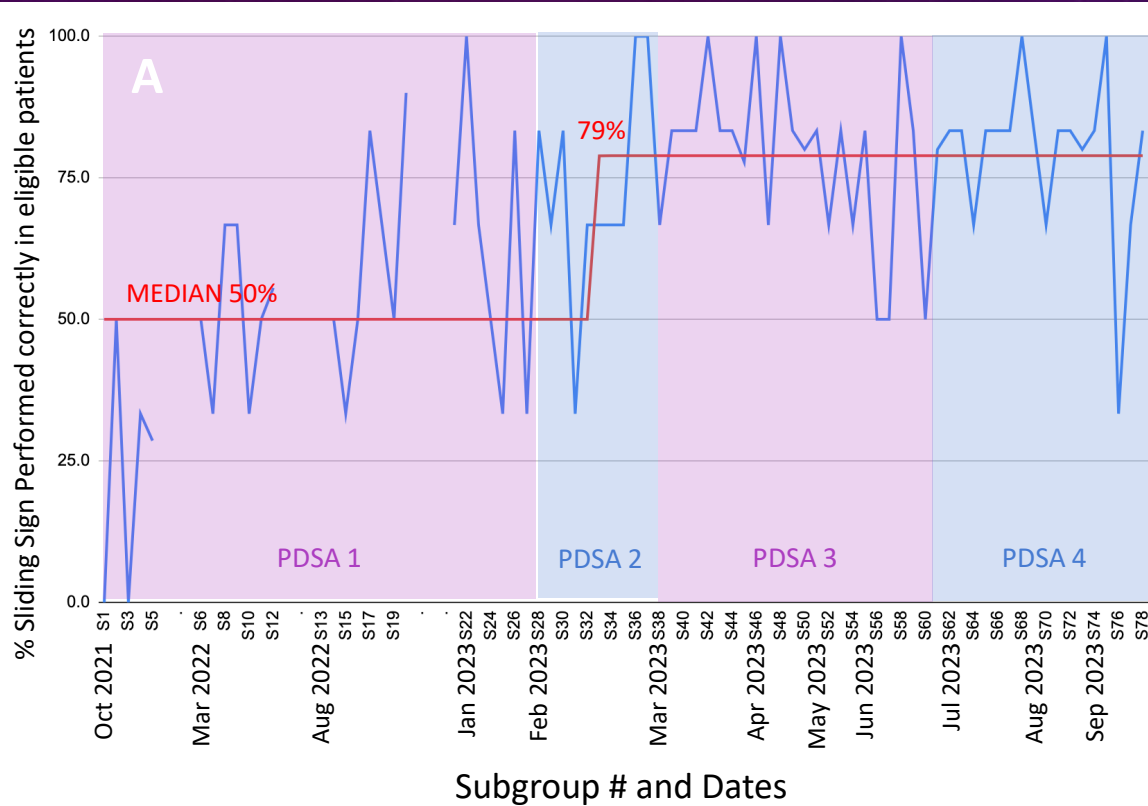
Evaluation of results

1. Search for all pelvic ultrasounds performed in each 4 week period
2. Filter out patients who do not meet eligibility criteria
3. Review imaging and reports of eligible patients and record:
 - How many patients had sliding sign performed
 - How many sliding sign cases performed correctly
 - How many final reports mentioned the sliding sign result
 - How many sliding sign cases interpreted and reported correctly in the final report
 - Estimate the extra time the sliding sign added to the ultrasound study
4. Search all abnormal sliding sign cases and follow-up chart review – how many had a confirmed or excluded diagnosis of endometriosis

Indeterminate cases – resolved by consensus opinion two expert readers

For each 4 week period – for purposes of data analysis the cases were divided into subgroups of 6 consecutive cases due to highly variable numbers of cases per week.

RESULTS

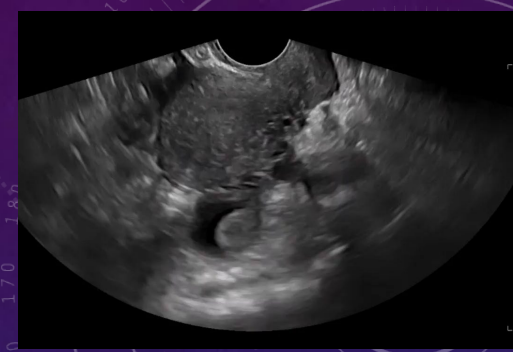

Run Chart Depiction of Results

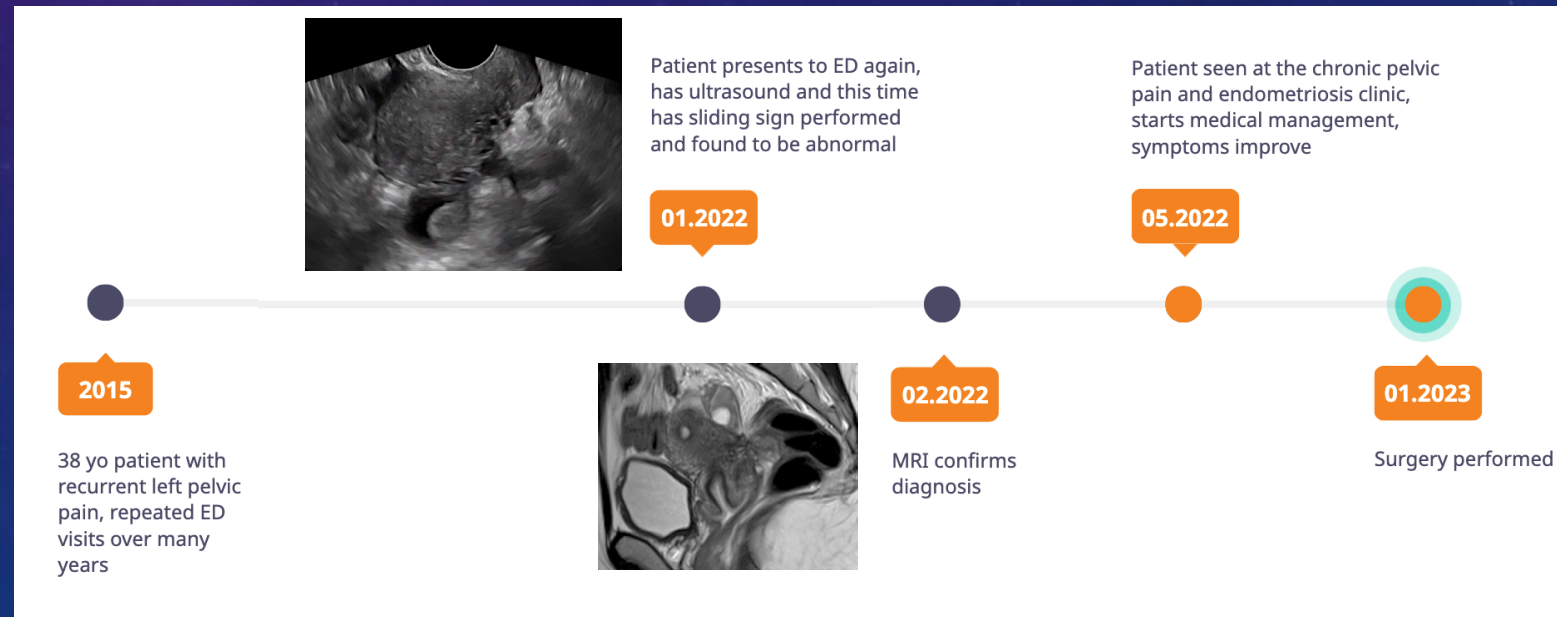
The x-axis indicates the chronological subgroups and specific timeline, y-axis on the left % of sliding sign performed correctly in eligible patients (A), on the right % of sliding sign reported/interpreted correctly in the final report (B). Median % (red) is 0 at baseline, increasing to 50% (A) and 33% (B) with PDSA cycle 1. Second change signal detected during PDSA cycle 2 with median increasing to 79% (A) and 67% (B). This is sustained through PDSA cycles 3 and 4 and appears to plateau. PDSA cycle 5 data pending.

RESULTS

- Extra time added to study by sliding sign cine loops ranges from 5-20 seconds
- For all abnormal sliding sign cases from Nov 2021 to Nov 2022 for which 12 month follow-up data was available:
 - 58 cases of reported abnormal sliding sign
 - 22 (38%) were newly diagnosed with endometriosis subsequent to sliding sign ultrasound (confirmed by surgery, specialized ultrasound, MRI, or clinical diagnosis by gynecology)
 - 25 (43%) had a previously known diagnosis of endometriosis on chart review
 - 8 (14%) no further follow up
 - 2 (3%) had surgery without findings of endometriosis
 - i.e. false positive, however in retrospect one of these cases may have been mis-interpreted as an abnormal sliding sign



Timeline of an example patient who had endometriosis newly diagnosed as a result of the sliding sign initiative and subsequently expedited referral to the appropriate specialists. (Video of abnormal sliding sign on next slide)



DISCUSSION

- Initial uptake/buy-in by sonographers >> radiologists, and improves significantly with on-site visual reminders.
 - Aim almost achieved for sliding sign performance in eligible patients.
- Challenges – consistent reporting of sliding sign by radiologists (especially non-abdo subspecialists) requires further effort to reach aim.
- Impact on ultrasound department workflow minimal (extra time required to perform less than 1 min)
- Sliding sign initiative resulted in a significant number of new diagnoses of endometriosis at our institution
- Anecdotally, gynecologists have been finding it helpful to guide further diagnostic workup and pre-operative planning
- Future directions
 - Further ingrain in processes – ex. tech worksheet and reporting template with mandatory fields
 - Spread initiative to other sites
 - Spin-off studies - Evaluate inter-reader variability, correlate abnormal sliding sign cases specifically to surgically proven posterior cul-de-sac obliteration